



Cite this: *J. Mater. Chem. B*, 2023, 11, 9369

Comprehensive evaluation and advanced modification of polymethylmethacrylate cement in bone tumor treatment

Bo Chao, Jianhang Jiao, Lili Yang, Yang Wang, Tong Yu, He Liu, Han Zhang, Mufeng Li, Wenjie Wang, Xiangran Cui, Shangyu Du, Zhonghan Wang* and Minfei Wu *

Bone tumors are invasive diseases with a tendency toward recurrence, disability, and high mortality rates due to their grievous complications. As a commercial polymeric biomaterial, polymethylmethacrylate (PMMA) cement possesses remarkable mechanical properties, injectability, and plasticity and is, therefore, frequently applied in bone tissue engineering. Numerous positive effects in bone tumor treatment have been demonstrated, including biomechanical stabilization, analgesic effects, and tumor recurrence prevention. However, to our knowledge, a comprehensive evaluation of the application of the PMMA cement in bone tumor treatment has not yet been reported. This review comprehensively evaluates the efficiency and complications of the PMMA cement in bone tumor treatment, for the first time, and introduces advanced modification strategies, providing an objective and reliable reference for the application of the PMMA cement in treating bone tumors. We have also summarized the current research on modifications to enhance the anti-tumor efficacy of the PMMA cement, such as drug carriers and magnetic hyperthermia.

Received 1st July 2023,
Accepted 28th August 2023

DOI: 10.1039/d3tb01494k

rsc.li/materials-b

1. Introduction

Bone tumors are nociceptive diseases characterized by severe recurrence, disability, and high mortality rates^{1,2} and can be classified as benign or malignant according to biological behaviors. Benign bone tumors include diverse tumors and are

distinct in incidence and clinical presentation.³ Malignant bone tumors include metastatic and primary bone tumors.⁴ Osteosarcoma is the most frequently occurring primary malignant tumor that originates from the bone. In contrast, metastatic malignant bone tumors are always derived from terminal lung, breast, and prostate cancer.⁵⁻⁷ Intermediate bone tumors are also regarded as a type of bone tumor, such as the giant cell tumor of the bone (GCTB).^{8,9} Whatever the type of bone tumor, it can constitute a serious threat to the patient's quality of life and is responsible

Orthopaedic Medical Center, The Second Hospital of Jilin University, Changchun 130041, P. R. China. E-mail: wangzhonghan@jlu.edu.cn, wumf@jlu.edu.cn



Bo Chao

Bo Chao was born in Inner Mongolia, China. He received his BS degree in 2021. He is currently pursuing his MS degree under the guidance of Prof. Minfei Wu in the Department of Orthopedics, Second Hospital of Jilin University. His research interests are focused on the multifunctional therapy of bone tumors and the modification of bone cement.



Zhonghan Wang

Zhonghan Wang is an attending doctor in the Orthopedic Department at the Second Hospital of Jilin University. He received his BS degree from Central South University in 2015, obtained his MS degree from Jilin University in 2018 and his MD degree in 2022. His research mainly focuses on preparing anti-tumor materials and regenerative medicine of the skeletal system.



for grievous complications, involving pathological fractures, osteolysis, hypercalcemia, and extreme pain.^{10,11} Pathological compression fracture, spinal cord compression, and even paraplegia frequently afflict patients when cancer occurs in the spine.¹²

The current clinical treatment of bone tumors is predominantly surgical curettage but is generally accompanied by extensive bone defects.^{13,14} Notably, the most fundamental intrinsic property of bone tissue, stability, will disappear following surgical curettage without filling implants.^{15,16} In addition, clinical judgment of complete tumor eradication is unreliable, depending only on rapidly frozen sections and the experience of surgeons,¹⁷ resulting in residual tumor cells frequently remaining around bone defects, which are insensitive to radiation with a tendency to resist chemotherapy.^{18–20} As a result, the recurrence of post-operative bone tumors and persistent pain are frequent, and these issues necessitate more effective treatment.

Polymethylmethacrylate (PMMA) cement generally serves as a substitute for bone, with the advantages of being plastic, injectable, with high mechanical strength and the ability to fill defects caused by orthopedic diseases or surgical resection.^{21,22} PMMA cement is a double-phase system composed of polymer powder and monomer liquid.^{23,24} The polymer powder principally consists of spherical PMMA beads and benzoyl peroxide (BPO). The monomer liquid is mainly methyl methacrylate (MMA) and *N,N*-dimethyl-*p*-toluene (DmpT).²⁵ While mixing the two phases, BPO reacts with DmpT to produce free radicals (benzoyl radicals and benzoyl anions), and the polymerization of MMA into PMMA will be subsequently initiated by conjugating to the polymerizable double bonds of the monomer molecules and the creation of a productive center. In addition, theoretically, PMMA cement generates heat during the polymerization reaction, killing the residual tumor cells around tumor defects by the exothermic polymerization reaction.^{26,27} Nevertheless, only tumor cells in an extremely restricted area

will be killed by the exothermic polymerization reaction, and healthy bone tissue may be damaged as a result.^{28,29} Most scholars conclude that the neurological symptoms of tumor-derived bone defects filled with PMMA cement are significantly relieved, and the rate of tumor recurrence and secondary fracture are also reduced compared to patient bone defects without PMMA cement.³⁰ However, some perspectives indicate that the absence of robust evidence to prove the risk of tumor recurrence can be reduced by filling tumor-derived bone defects with PMMA cement.^{31,32} There are also many reports of complications when using PMMA cement, such as cement leakage,^{33,34} cardiac tamponade,³⁵ dislodgement of cement,^{36–38} osteoarthritis,^{39,40} etc.

The aseptic loosening of PMMA cement may occur after injecting it into the tumor-derived bone defect due to the progressive growth and osteolysis of residual cancer cells.^{41,42} To avoid this situation, improving the tumor inhibition efficiency of cement is a reasonable method. Chemotherapeutics-loaded PMMA cement is the most common and accessible approach to modification.^{43,44} The local concentration of chemotherapeutics is prominently increased by chemotherapeutics-loaded PMMA cement, while the plasma concentration of chemotherapeutics is significantly reduced, which effectively weakens the extent of systematic side effects.⁴⁵ In addition to being optimized as a drug carrier, PMMA cement can also be modified to possess magnetic hyperthermal capability.⁴⁶ Magnetic hyperthermia, as an adjuvant treatment for cancer treatment, will kill tumor cells at high temperatures.^{47,48} The appropriate temperature between 41 °C and 45 °C will be generated in an alternating magnetic field (AMF) by mixing magnetic thermal seeds into PMMA cement.⁴⁹ Notably, the benefits of PMMA cement in the treatment of bone tumors will be prominently improved by both modification methods.

In this review, the efficiency of PMMA cement in the treatment of bone tumors is comprehensively introduced, including biomechanical stabilization, the analgesic effect, and tumor recurrence prevention. In addition, the possible complications of PMMA cement during treatment will also be presented objectively. The advantages and disadvantages of the current clinical application of PMMA cement are compared and discussed, which is convenient for weighing the pros and cons more rigorously. Moreover, we also discuss the advanced modification approaches of PMMA cement and its benefits. This review aims to evaluate the various functions of PMMA cement and possible complications in bone tumor treatment, further introducing advanced modification methods, to provide an objective and reliable reference for the application of PMMA cement in treating bone tumors (Scheme 1).

2. Evaluation of PMMA in bone tumor treatment

Currently, the major clinical treatment for bone tumors is surgical resection, which frequently involves large bone defects that require PMMA cement as an orthopedic implant to fill and



Minfei Wu

Minfei Wu received his MD degree from the Orthopedic Department, at the Second Hospital of Jilin University in 2014. During this period, he worked as a visiting scholar at the Massachusetts General Institute affiliated with Harvard University. At present, he is a vice-principal, professor, chief physician, and doctoral supervisor at the Second Hospital of Jilin University. His research mainly focuses on the treatment of spinal tumors and the minimally invasive treatment of spinal cord injuries. He has designed a series of novel biomaterials for bone tissue engineering, including low-temperature bone cement sustained-release carrier materials, magnesium-based anti-tumor implants, and 3D printing topology-optimized spinal implants.

Minfei Wu received his MD degree from the Orthopedic Department, at the Second Hospital of Jilin University in 2014. During this period, he worked as a visiting scholar at the Massachusetts General Institute affiliated with Harvard University. At present, he is a vice-principal, professor, chief physician, and doctoral supervisor at the Second Hospital of Jilin University. His research mainly focuses on the treatment of spinal tumors and the minimally invasive treatment of spinal cord injuries. He has designed a series of novel biomaterials for bone tissue engineering, including low-temperature bone cement sustained-release carrier materials, magnesium-based anti-tumor implants, and 3D printing topology-optimized spinal implants.





Scheme 1 Schematic illustration of the comprehensive evaluation and advanced modification of PMMA cement in the treatment of bone tumors.

provide mechanical support. Therefore, the application of PMMA cement in bone tumor treatment was evaluated systematically in this section, including biomechanical stabilization, the analgesic effect, prevention of recurrence, and complications.

2.1. Maintaining biomechanical stabilization

Healthy bone tissue possesses stable self-healing ability. However, such self-healing ability is restricted to the repair of small bone defects and is only achievable in the presence of a healthy bone tissue microenvironment.⁵⁰ Critical bone defects caused by surgical curettage or osteolytic bone tumors make it difficult to restore normal physiological structure without medical intervention.⁵¹ Autologous bone grafting is an ideal filler with a high success and fit rate. Nevertheless, restricted availability of autogenous bone, infection tendency, massive blood loss, *etc.*, are all adverse factors in clinical autologous bone grafting.^{52,53} Therefore, contemporary researchers and surgeons have used various biomaterials as substitutes for bone tissue.⁵¹ PMMA cement is one of the most popular biomaterials, characterized by injectability, plasticity, convenience, and good mechanical properties.^{54,55} Since the shape and the area of the bone defect can be neatly matched by PMMA cement, it plays a crucial role in the reconstruction of the stability of tumor-derived bone defects.

2.1.1 Restoration of spinal stability. PMMA cement is mostly applied to spinal metastases as a filler for tumor-derived bone defects. The spine is one of the major weight-bearing organs of the body and the most frequent metastatic locale for malignant tumors with a metastatic rate of up to 70%.⁵⁶ Therefore, the primary aim of reconstructive surgery after spinal tumor decompression is to restore spinal stability.⁵⁷ Scoville *et al.*⁵⁸ first demonstrated the feasibility of PMMA-assisted anterior reconstruction in a patient suffering from

spinal metastases in 1967. The recovery of spinal function with the slightest damage is the major advantage of PMMA cement in vertebral replacement due to the limited life expectancy of patients, who should not be immobilized in the bed by plaster or traction in the final months but rather have quality of life through spinal reconstruction.⁵⁸ In addition to patients with limited anticipated survival, reliable therapeutic results were demonstrated over a 13 year follow-up using PMMA cement in one patient with spinal metastases. The anterior bone fusion was firm and the stability of the vertebral body was restored significantly as observed in the computed tomography (CT) imaging 13 years after the operation.⁵⁹ Percutaneous vertebroplasty (PVP) is a minimally invasive procedure that can infuse PMMA cement and restorative vertebral body structure.^{60,61} Wong *et al.*⁶² examined this procedure as ideal in situations where bone strengthening is required in patients with spinal metastasis. After filling the bone defect through PVP, the patient reported being able to recuperate mobility independently in the immediate postoperative phase.⁶² PVP showed good efficacy in the reconstruction of single spinal metastases but the stability of the reconstruction of multilevel spinal metastasis is unsatisfactory, even with temporary paraparesis.⁶³ Therefore, a modified treatment of PMMA has been proposed for the reconstruction of multilevel spinal metastasis. In a study of patients with spinal metastases fixed with PMMA-augmented screws, two of the four patients who were unable to walk regained the ability to walk immediately after surgery. During the 7 month follow-up, no vertebral collapse was observed in all patients.⁶⁴ Therefore, screw fixation augmented with PMMA cement can provide dependable stability for multilevel spinal metastasis. In bone cement-augmented pedicle screw fixation combined with vertebroplasty, also known as the sandwich procedure with an execution sequence, PMMA cement was injected first after tumor curettage, and then pedicle screws were tightened when the PMMA cement was solidified.⁶⁵ The efficacies of PVP- and bone cement-augmented pedicle screw fixation were compared in the treatment of spinal metastases, and subtotal vertebral resection with pedicle screw fixed reconstruction showed better efficacy.⁶⁶ All of the above treatments are anterior column vertebral reconstructions of spinal metastasis, and complex vertebral reconstruction requires improved procedures. In the case of a three-column osteotomy of the spinal defect, multiple auxiliary rods were required to support the strength of the structure of the sandwich procedure. The multiple-rod constructs had a lower overall hardware failure rate than the single-rod ones. The strength of the cement-augmented quadruple rod constructs provided reliable stability for patients with complex neoplastic vertebral defects.⁶⁷

2.1.2 Restoration of the stability of limbs. The tumor-derived defects of the vertebral body can be repaired with PMMA but it also can be applied to defects in limbs and other bones to restore stability, especially for bed-ridden patients with contraindications to surgery. A patient with osteolytic defects in the proximal humerus with a life expectancy of less than 1 month was administered PVP to provide axial loading with minimal damage by filling PMMA cement.⁶⁸ Even for children with immature skeletons, PMMA cement as a structural



strengthening material can be used to improve the mechanical stability of the bone, despite requiring the postoperative removal of the PMMA cement to avoid disturbing growth.⁶⁹ GCTBs, generally present in the distal femur, are frequently conducive to severe fractures after surgical curettage.⁷⁰ Injecting PMMA cement after the curettage of GCTBs can significantly restore the function of limb bones.^{71–75} In the report by Alejandro *et al.*,⁷⁶ the use of bone cement after the curettage of the GCTB lesion is a better choice than allogeneic bone because adequate structural support for the bone in knee reconstruction can be provided by PMMA cement. Another study also explicated that filling PMMA cement after curettage of GCTBs not only reconstructed the tumor-derived bone defects but also reduced the risk of postoperative fracture. However, additional plate fixation will be considered if PMMA cement treatment is not an option, which increases the difficulty and the cost of surgery.⁷⁷ A new surgical technique for subchondral bone grafting combined with PMMA cement reconstruction was developed for the treatment of GCTBs, which can more adequately restore the subchondral and cancellous positions of the joint surface with minimal mechanical problems (Fig. 1). The optimal recovery of structural integrity and limb function was achieved postoperatively.⁷⁸ In addition, encouraging results were obtained with the treatment of osteolytic cancer in the pelvis with PMMA cement. All postoperative patients

were able to walk independently with the loading-operated limb, and the patients appreciated the significant improvement in their quality of life.⁷⁹

2.2. Analgesic effect

In addition to skeletal instability, the risks of pathologic fractures or nerve compression will be increased by bone tumors. The subsequent tormenting pain or paralysis severely damages the quality of the patients' lives if not treated expeditiously.^{80,81} The neurophysiological mechanisms of cancer pain may be implicated in neurochemicals produced by tumors and inflammatory cells, of peripheral sensitization due to nerve compression and injury caused by tumor growth.^{82,83} Affected by the continuous erosion of residual cancer cells into the surrounding bone tissue and nerves, neurogenic bone pain may be stimulated by the disturbance of the highly innervated periosteum.⁸⁴ Another cause of pain is the instability of pathological fracture, imposing a compulsive position on patients.⁸⁵

Regardless of the cause of bone pain, filling PMMA cement in tumor-derived bone defects can effectively relieve neurological symptoms in patients. The main principles are as follows. (1) With the penetration of PMMA cement into the interspace of the partially fractured bone trabeculae, the strength and original stability of bones are restored to the greatest extent. (2) The heat and chemically toxic substances generated from the polymerization reaction of PMMA cement kill the eroded nociceptive nerve endings and the residual tumor cells.^{86,87} The application of PMMA cement in relieving neurological symptoms will be introduced in this section.

2.2.1 Relieving bone pain. A certain curative effect on painful bone tumors will be presented by radiotherapy but it cannot correct the instability of bones. Therefore, the radiotherapeutic effect is usually mediocre in relieving the neurological symptoms of patients with bone tumors.^{88,89} To verify that PMMA cement can indeed improve the symptoms of pain in patients with bone tumors, a patient with lumbar spinal tumors from thyroid follicular carcinoma tried analgesic agents, external beam radiation therapy, radioiodine therapy, and posterior fusion surgery but the pain still reemerged and progressed⁹⁰ until the pain was significantly relieved after PVP. At least as illustrated in this case, PVP can be used as an alternative pain relief method for patients with vertebral tumors. PVP is a reliable treatment for pain relief, which was also illustrated by the significant reduction in the mean amounts of non-narcotic and narcotic analgesic after surgery as compared with before surgery.⁹¹ Even for intractable pain, PVP is an effective alternative for pain relief.⁹² Further explanation of the mechanism is provided by the principles described above, whereby the heat and chemical toxicity of the PMMA cement polymerization reaction kills the eroded nociceptive nerve endings, thus relieving the bone pain immediately.^{86,87} In another retrospective analysis of patients whose primary presentation was pain and neurological impairment, the neurological status was improved in 60% of patients after injecting PMMA cement for vertebral metastases; 81% of the patients in this study were satisfied or very satisfied with the effect of pain

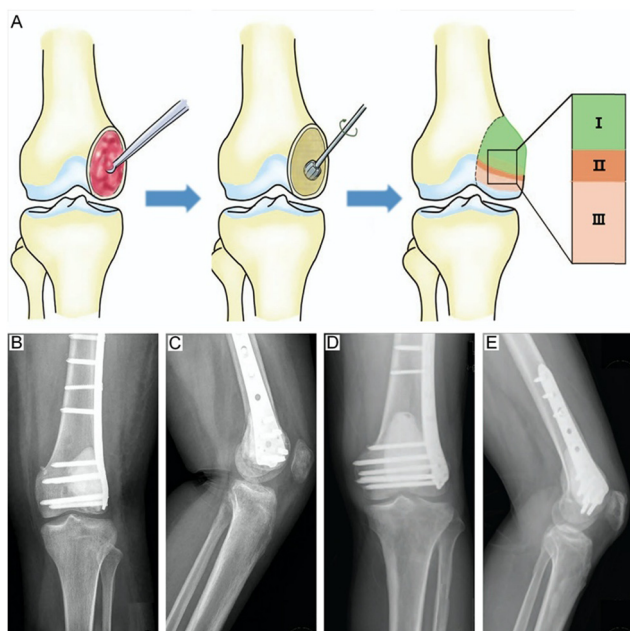


Fig. 1 Schematic diagram of PMMA cement implantation after GCTB removal. (A) Schematic illustration of GCTB curettage showing an appropriately sized cortical window and the application of a high-speed burr to eliminate pockets of residual tumors in the cavity, followed by grafting of subchondral cancellous bone and cortical bone. (I) PMMA cement implant area. (II) Cortical bone grafting area. (III) Subchondral cancellous bone grafting area. (B) and (C) Follow-up X-rays at 25 months demonstrated excellent plasticity of the subchondral bone graft without joint degeneration. (D) and (E) Follow-up X-rays showed good plasticity of the subchondral bone graft without joint degeneration. Reproduced with permission.⁷⁸ Copyright 2018, Wolters Kluwer Health.



relief.⁹³ Yang *et al.*⁹⁴ illustrated the idea that PMMA cement provides biomechanical stability for pain relief in fragile vertebrae by reviewing 57 patients without new or adjacent vertebral fractures within two years after PVP. More effective pain relief would be demonstrated by PVP combined with radiotherapy than PVP by itself. Patients with osteolytic metastatic spinal tumors were treated with radiotherapy to suppress the tumor or induce pain relief immediately after PVP.⁹⁵

2.2.2 Relieving neurological compression. In combination with the mechanism of cancer pain,⁸² an alternative mechanism in which PMMA cement can be effective in relieving pain is to relieve nerve compression, as bone eroded by tumor cells often becomes structurally unstable and then compresses nerve roots or the dural sac. Although some opinions on tumor-epidural encroachment are a relative contraindication to PVP,^{96,97} the choice of PVP for painful spinal metastases in patients with epidural encroachment remains a controversial issue. A retrospective study was the first to review the efficacy and safety of patients with epidural encroachment treated by PVP. In the postoperative follow-up of 51 patients included in the study, the effective pain relief rate was 94% at 1 day and 92% at 1 year, which was evaluated by the Kaplan–Meier survival curve and with a low complication rate.⁹⁸ In addition, an appreciable effect of analgesia was also demonstrated in other retrospective studies of patients with epidural spinal metastases treated by PVP.^{99,100} Li *et al.*¹⁰¹ designed an innovative approach, PVP combined with interventional tumor removal (ITR), which can better relieve symptoms of neurological compression than PVP. The main advantage is that PVP after ITR eliminates residual tumor tissue as much as possible, providing long-term pain relief. Radicular pain related to the malignant tumor compressing the dorsal root ganglion was also significantly relieved after PVP.¹⁰² Severe pelvic bone metastasis often causes pain and gait disturbance. As shown in Fig. 2, the percutaneous injection of PMMA cement into the pelvis is a feasible and safe palliative surgical option for pain management, and not only relieves pain under local anesthesia but can also maintain walking function.¹⁰³

2.3. Preventing recurrence

The recurrence of bone tumors often contributes to many grievous problems for patients and clinical management. Once the tumor recurs, the patient will not only suffer from the administering of additional treatment even reoperation, but more seriously, the patient's condition will continue to worsen.¹⁰⁴ Local recurrence of spinal metastasis is relatively common, even after aggressive surgery. Moreover, spinal column instability and spinal cord compression will always occur consequently.¹⁰⁵ However, due to the limited life expectancy of patients with spinal metastasis of malignant tumors, most of them died without retrospective statistics. As intermediate bone tumors, the recurrence rate of GCTBs is still high, attributed to narrow surgical margins.¹⁰⁶ Whether patients with GCTBs treated with PMMA cement have a lower recurrence rate is consistently controversial and will be summarized and discussed in this section. For a more straightforward overview of



Fig. 2 Representative images of percutaneous pelvic cementoplasty. (A) and (B) T1-enhanced magnetic resonance imaging and computed tomography imaging showing osteolytic bone metastases with cortical defects in the right acetabulum. (C) Post-operative X-ray showing reinforcement of the acetabulum. (D) Positron emission tomography-computed tomography images showing disease progression at 15 months postoperatively, except at the right acetabulum (upper, preoperative; lower, 15 month postoperative status). Reproduced with permission.¹⁰³ Copyright 2021, Springer Nature.

different perspectives, we have compiled the relevant research of different perspectives in Table 1.

2.3.1 Supporting perspectives. Kivioja *et al.*¹⁰⁷ reported that local recurrence rates following surgical curettage would be prominently decreased by PMMA cement, supporting the comprehensive preferential use of PMMA treatments. Similar results were reported in another study, in which 22% of GCTB patients treated with PMMA cement and 49% of GCTB patients treated with bone graft emerged with local recurrence within 63 months, evidence that further supports applying PMMA cement to inhibit the recurrence of GCTBs.¹⁰⁸ Another systematic review and meta-analysis compared the efficacy of PMMA and allogeneic bone grafting following intralesional curettage GCTBs. The recurrence rate of GCTB patients who were administered PMMA cement repair after surgical curettage was relatively lower than that of patients who received bone grafting (RR 2.09, 95% confidence interval (1.64, 2.66), overall effect: $Z = 6.00$; $P < 0.001$).¹⁰⁹ The burring of the cavity with a high-speed air drill followed by PMMA cement effectively inhibited the tumor recurrence.^{110,111} Some studies have also explored new technology and found that the combination of radical curettage, phenol irrigation, electrocautery, and PMMA cement could effectively prevent local recurrence.^{112,113,118} Even without any chemical or physical local adjuvant therapy, combination treatment followed by radical curettage, phenol irrigation, electrocautery, and PMMA cement could still obtain satisfactory results with a low recurrence rate.¹¹⁴



Table 1 Different perspectives on whether PMMA cement-treated patients with bone tumors have decreased recurrence rates

Different perspectives	Summation	Ref.	
Supporting perspectives	In the subgroup of 200 patients surgically treated within the lesion, filling PMMA cement was administered in 194 patients and supported highly statistically significant administration of PMMA cement.	107	
	Using PMMA cement as an adjuvant significantly reduces the rate of recurrence after intralesional treatment of benign giant cell tumors, and it appears to be the preferred treatment for both primary and recurrent giant cell tumors of bone.	108	
	Minimal local recurrence rates were achieved in PMMA-treated patients, indicating that PMMA is more appropriate as a routine clinical treatment for eligible patients with GCTB.	109	
	Recurrent GCTB treatment is available by further curettage with subsequent debridement and PMMA, with an acceptable re-recurrence rate of only 21.7%.	110	
	The combination of all adjuvants (PMMA, burring, H ₂ O ₂ – n = 42) reduces the probability of recurrence by 28.2-fold relative to curettage alone and should therefore be recommended as standard treatment.	111	
	The combination of curettage, phenol flushing, electrocautery, and PMMA is effective in preventing local recurrence and can replace en bloc resection with large margins.	112	
	The combination of burring, argon plasma cauterization, phenolisation, and PMMA cement in GCTB treatment is a safe and effective procedure to reduce the rate of local recurrence.	113	
	Satisfactory function at mid-term follow-up, low recurrence rate, and effective treatment of GCTB with locally enlarged curettage, electrocautery, and PMMA cement.	114	
	Opposing perspectives	Analyzing the results of 49 patients with forearm GCTB treated from 2 to 28 years, the highest number of recurrences was in patients who received autograft or PMMA cement after curettage.	115
		There was no effect of PMMA cement use on recurrence rates compared with bone grafting (RR, 0.98; 95% CI, 0.44–2.17).	116
PMMA cement is not regarded as a local adjuvant to prevent the recurrence of bone tumors; it is simply a mechanical reinforcement of the tumor cavity.		117	

2.3.2 Opposing perspectives. Many opinions indicate that PMMA cement is not an independent factor in reducing the tumor recurrence rate. There was no difference in recurrence rates in several studies that directly compared patients who received PMMA cement *versus* bone grafts.^{115,116,119} PMMA cement is not supposed to be a local adjuvant to tumor cells after curettage but rather a mechanical reinforcement of tumoral defects according to Jacob *et al.*¹¹⁷ Although there is still controversy about whether PMMA alone can reduce the rate of tumor recurrence, it was confirmed that PMMA cement possessed ideal radiological features to identify local recurrence;^{120,121} moreover, the tumor recurrence rate can effectively be reduced by PMMA-related combination treatment.^{112,113}

2.4. Complications

The multifunctional role of PMMA cement in the treatment of bone tumors was introduced above. Reconstructing tumor-derived bone defects, relieving neurological symptoms, and inhibiting tumor recurrence have been achieved with considerable efficacy. However, the technique of injecting PMMA cement for the treatment of bone tumors is not without pitfalls.¹²² This section summarizes the challenges and potential complications during the administering of PMMA cement to facilitate predicted detection, provide treatment recommendations for complications, and minimize procedural risks.

2.4.1 Thermal damage. Thermal heat from the polymerization reaction of PMMA cement kills residual tumor cells and pain nerve endings, as confirmed above.^{86,87} However, thermal damage may significantly risk overkill, injuring substantial amounts of healthy tissue.¹²³ There was even research indicating that thermal damage to the spinal cord during PMMA cement application may be more predominant in the grey matter compared to other neural tissues.¹²⁴ For injecting PMMA cement around the distal femur or proximal tibia, thermal damage to the adjacent articular cartilage occurs

relatively frequently. Radev *et al.*¹²⁵ determined possible thermal damage around PMMA by finite element analysis, implants (8–24 cc in volume) placed into a peripheral metaphyseal defect in the proximal tibia. The result indicated thermal injury to both normal bone and remaining tumor cells in the vicinity of the PMMA implant at the time of its polymerization. Although the necrotic effect extends only to limited areas surrounding bone, the surrounding cancellous and subchondral bone will be damaged. Mechanical vulnerability and the collapsing of bone under joint loading might be a consequence. In comparative research on the depth of tissue necrosis caused by different adjuvant therapies after bone tumor curettage, the average depth of tissue necrosis of PMMA cement was 0.78 mm. The authors also indicated that the exothermal effect of PMMA cement is associated with volume, and the depth of tissue necrosis caused by PMMA cement may be underestimated as compared to the actual clinical application.¹²⁶

Tissue necrosis caused by the exothermal effect of PMMA cement is a risk factor for osteoarthritis. A retrospective single-center study involved fifty-three patients with GCTBs around the knee treated with curettage followed by PMMA cement; after the procedure, 17% of patients had radiographic findings of osteoarthritis.³⁹ To safeguard against osteoarthritis, an insulating layer between the PMMA cement and articular cartilage was utilized to protect the articular cartilage. This insulating area was created using oxidized cellulose and subchondral cancellous allograft after the PMMA cement had completed polymerization. The intermediate outcome follow-up of this patient with GCTB has been promising.¹²⁷ Another novel subchondral bone grafting procedure was proposed by Wu *et al.*⁷⁸ to reduce the risk of osteoarthritis. It involved packing autogenous bone grafts, approximately 10 mm thick, in the subchondral bone defect, followed by filling PMMA cement in the remaining cavity. This novel bone-grafting procedure increased the distance between the exothermic reaction of PMMA cement



and the articular cartilage, thereby reducing the pressure on the cartilage and subchondral bone layer. Similarly, Joseph *et al.*¹²⁸ also indicated that patients with additional subchondral bone grafts after curettage had significantly fewer postoperative complications, including fractures and arthritis, and this did not increase the probability of tumor recurrence as compared with PMMA cement alone.

The temperature during the exothermic polymerization of PMMA cement *in vivo* contributes to the thermal necrosis of osteoblasts and impaired local circulation, which potentially lead to premature failure.¹²⁹ Moreover, the degree of heat generated throughout the polymerization is influenced by the amount of reacting monomer.¹³⁰ In summary, the distance between the heat of PMMA polymerization and the articular cartilage will be increased by bone grafting, which can prevent thermal damage. Alternatively, flushing the surrounding area with frozen saline as a cement-curing agent can prevent thermal necrosis.

2.4.2 Cement leakage. The anterior and posterior walls of the vertebral body are frequently destroyed by invasive spinal metastases. Therefore, cement leakage often occurs after using PMMA cement for spinal reconstruction, including cortical cement leakage and vascular cement leakage,¹³¹ which is associated with risks of mechanical damage to the anterior aorta and posterior spinal cord of the vertebral body.^{132,133} Cement leakage is responsible for the procedure's location and needle approach.¹²² Moreover, incomplete posterior wall and injection volume are risk factors for vascular cement leakage,^{134,135} patients with posterior wall defects are often associated with a higher risk of cement leakage.¹³⁶ Although this situation of cortical cement leakage is usual, most patients with cement leakage do not manifest corresponding clinical symptoms.^{137–140} Symptoms caused by cortical PMMA leakage can be relieved through the appropriate hormone and analgesic treatment.⁹²

PMMA emboli formed by cement leakage can also transfer from the paravertebral veins to the inferior vena cava, renal vein, right heart, or pulmonary arterial system,^{63,141,142} even the dorsal pedal artery.¹⁴³ As shown in Fig. 3, the cement leakage appeared in the eighth thoracic vertebra. The majority of PMMA emboli are small without any clinical manifestations, and no additional treatment is required.⁶³ However, cases of severe cardiopulmonary complications also occur occasionally.¹⁴⁴ There has been a report of fatal pulmonary embolism caused by PMMA cement,¹⁴⁵ and a case of cardiac perforation caused by PMMA escaping into the vascular system was reported by Zhang *et al.*¹⁴⁶ Even if it occurs in the administration of fracture treatment, more precautions should be taken in the procedure of bone tumor treatment. In addition, the displacement of bone marrow into the periosteal venous plexus may be attributed to intensive pressure during cement injection that travels to the pulmonary circulation as fat emboli.^{147–149}

To avoid cement leakage, Li *et al.*¹⁵⁰ indicated that tumor tissue should be completely eliminated before PMMA injection to create voids and subsequently, the occurrence rate of complications will be relatively reduced. Vertebral body lavage



Fig. 3 Representative images of cement leakage. Postoperative X-ray images show most of the PMMA cement located within the vertebral body, with very slight leakage outside of the eighth thoracic vertebra but not into the spinal canal. Reproduced with permission.⁶³ Copyright 2020, SAGE Publications Ltd.

before PMMA injection,¹⁵¹ and limiting the PMMA injection to less than 30 ml per vertebral body will also prevent the formation of fat embolisms.¹⁵² Whatever, rigorous monitoring is the primary measure to reduce the risk of PMMA leakage,¹⁵³ additional scaffolds can also provide a barrier function for cement.^{154,155} Some novel biomaterials exhibited appreciable effects in preventing the leakage of PMMA, such as high-viscosity cement,^{156–158} and composite membranes.^{159,160} Comprehending probable complications can optimize treatment options, innovate techniques, guide perioperative management, and provide a credible reference for researchers in the future.

3. Modification of PMMA to enhance the anti-tumor efficiency

As understood from the previous content of this article, various clinical manifestations or complications are primarily due to the residual tumor cells. Therefore, the eradication of residual tumor cells is the most essential issue. However, except for tumor cells in an extremely limited range that will be killed by the exothermic polymerization reaction of PMMA cement, residual tumor cells with strong proliferative capacity rapidly proliferate and sequentially erode the bone tissues. To improve this dilemma, effective strategies are adapted for modifying PMMA cement. As shown, the strategies of advanced modification and functional evaluation of PMMA cement are summarized in Table 2.

3.1. Drug carriers

Patients are routinely administered antineoplastic drugs after surgery to prevent residual tumor cells.¹⁸¹ However, systemic administration is associated with difficulties in achieving appropriate local (target) drug concentrations and the local efficacy is diminished.^{182,183}





Table 2 Advanced modification and functional evaluation of PMMA cement

Modification strategies	Types of drugs	Mechanical properties	Functional evaluation	Ref.
Drug carrier	Simple drug delivery	The mechanical properties of cement were not altered.	The eluted cisplatin from PMMA exerts its cytotoxic action on Saos-2 cells, while the systemic concentration and the side effects are kept minimal	45
Porogens	Cisplatin	The cement modulus was not affected, but the strength varied based on the method and duration of storage.	Anticipating the potential value of drug delivery in PMMA for appendicular and axial spinal applications	161
	DOX/pamidronate Methotrexate	The compressive strength of cement was not reduced at any of the concentrations of MTX.	Confirming the MTX-supplemented cement can be used as an effective aid for the management of bone metastases	162
Porogens	Cisplatin/ methotrexate	—	The drug concentration in bone could be maintained for 5 weeks without myelosuppression, hepatotoxicity, and nephrotoxicity in the experimental study of pigs	163
	PEG/SBA-15	The compressive strengths of PMMA cement with varied contents of SBA-15 were all between 80 MPa and 85 MPa, and the binding strength of the bone cement decreased sharply from 112 MPa to 39 MPa.	A sustained drug release of up to seventy days can be achieved with sustained antibacterial activity but low toxicity to normal cells	164
Porogens	Colistin	Modulation of the mechanical properties of PMMA cement by varying the amount of CMC incorporated, with decreasing mechanical properties as the CMC increases, is expected to provide support for craniomaxillofacial structures.	Imparting PMMA cement porosity for sustained five-week drug release, but lacking bioassays to validate tumor suppression	165
	MTX	The addition of 1.6% (w/w) CMCs significantly increased the flexural modulus, flexural strength, and compressive strength of MTX-PMMA by 5%, 2.8% and 5.2% respectively.	CMCS enhances the killing effect of MTX on tumor cells while reducing the side effects associated with MTX, simultaneously guides tissue growth and satisfactory cement-bone union	166
Porogens	Gelatin	After 14 d of immersion in PBS, the compressive and flexural properties of the bone cement were significantly reduced, effectively reducing the risk of adjacent vertebral fractures caused by PMMA bone cement.	The release of GS in PMMA bone cement containing gelatine is 3.8 times higher than in conventional PMMA bone cement without gelatine, PMMA bone cement with 30% (w/w) gelatine maintains excellent antibacterial effect for at least 14 d in antibacterial tests	167
	PEG	—	PEG porogen increases the elution of MTX and mobilizes large amounts of the drug into the surrounding environment	168
Porogens	γ -CD	The threshold of 70 MPa was exceeded after 48 hours for plain PMMA and PMMA/1.25 wt% free-DOX, while PMMA/15 wt% CD-DOX was slightly below this threshold (6.6 MPa).	Over a period of 100 days, the composite PMMA/15 wt% CD-DOX released 100% of the initial DOX, while PMMA/1.25 wt% free-DOX released only 6% of the initial DOX; the ability to supplement additional doses of DOX after implantation contributes to the customization of personalized treatment programs.	169
	CMC	The addition of CMC reduced the fracture toughness, while the modulus of elasticity was significantly decreased.	The introduction of 3% CMC as a drug delivery vehicle and porogens for the sustained release of sufficient amounts of cisplatin and effective killing of osteosarcoma cells <i>in vitro</i> .	170
Radioisotopes	^{125}I seeds	—	Clinical efficacy can be enhanced by the combination of PVP and interstitial implantation of ^{125}I iodine seeds.	171
	^{125}I seeds	—	The combination of PVP with ^{125}I iodine seeds performs well in terms of rapid pain relief, improvement of daily living activities and the quality of patients' lives.	172
Magnetic hyperthermia	^{153}Sm -EDTMP	—	This procedure enhanced the anti-tumour potential for vertebrae with osseous metastasis without damaging adjacent tissues.	173
	Fe_3O_4	PMMA cement containing 60 wt% of 100–500 nm Fe_3O_4 MNP still achieved approximately 90 MPa compressive strength.	Bone cement samples containing 50 wt% MNP generates sufficient heat for the clinical application of bone tumors even in an alternating magnetic field of 120 Oe.	174
Magnetic hyperthermia	Fe_3O_4	—	The tumor was completely ablated at a dose of 0.1 ml, 10% PMMA- Fe_3O_4 , and a magnetic field exposure time of 180 s.	175
	Fe_3O_4	—	The feasibility of thermal therapy based on PMMA cement containing 22 wt% Fe_3O_4 was tested <i>ex vivo</i> in the beef	176

Table 2 (continued)

Modification strategies	Types of drugs	Mechanical properties	Functional evaluation	Ref.
Silica-coated MNP	—	Both the mixing method and the percentage of filler affect the strength of PMMA cement.	vertebrae, and multi-cycle heating of PMMA-MNP was also verified.	177
Zn _{0.3} Fe _{2.7} O ₄	—	Mixing the lower weight of MNPs with MMA monomer before mixing with PMMA powder can increase the mechanical strength of PMMA cement, providing reliable mechanical support.	The biocompatibility of the cement was revealed by <i>in vitro</i> studies. <i>In vivo</i> investigations show that PMMA-Zn _{0.3} Fe _{2.7} O ₄ meditative magnetic hyperthermia locally inhibits bone metastasis and suppresses osteolytic bone resorption.	178
TiO ₂ /Fe ₃ O ₄	—	—	Positive effects of TiO ₂ and Fe ₃ O ₄ content on apatite formation capacity and heat production characteristics of PMMA cement.	179
Fe ₃ O ₄	DOX	—	DOX/Fe ₃ O ₄ @PMMA can be injected minimally invasively into the tumor, which not only causes significant tumor regression but also enhances the efficacy of oncological chemotherapy by triggering the rapid release of encapsulated DOX from the PMMA cement without side effects.	46
Fe ₃ O ₄	—	The mechanical properties were all restored after injection of PMMA-6% Fe ₃ O ₄ and its conversion to a solid and were not statistically different from the normal tibial plateau in <i>ex vivo</i> measurements.	A novel, highly efficient, and minimally invasive method for complete bone tumor ablation and bone defect repair based on Fe ₃ O ₄ NPs-containing PMMA magneto-thermal ablation.	180

3.1.1 Simple drug delivery. To accomplish elevated local drug concentrations and enhanced therapeutic efficacy, researchers have applied PMMA as a drug carrier to combat local tumor recurrence and adverse impacts attributed to systemic drug exposure.¹⁶³ Such drug carriers are also regarded as drug delivery systems (DDS),¹⁸⁴ which are more secure, advantageous, and effective. In the study by Kazutaka *et al.*,⁴⁴ the anti-tumor effect even on lung metastases was employed using zoledronic acid (ZA)-loaded PMMA. This inspiration was initiated by the invention of the pioneering antibiotic-loaded PMMA cement as a measure to deliver a high local concentration of antibiotics to the peripheral tissues.¹⁸⁵ The current research on antibiotic-loaded PMMA cement is much more advanced than anti-tumor treatment, so many research insights can be applied to anti-tumor treatment.^{186,187}

Generally, PMMA powder is initially mixed with antineoplastic agents, including methotrexate (MTX), doxorubicin (DOX), ZA, and cisplatin, before being incorporated into the liquid component.^{45,161,163} On a few occasions, the drug was firstly compounded with the liquid component.^{188,189} Differences in drug elution efficiency exist between the two methods of mixing,¹⁹⁰ furthermore, the elution efficiency of drugs is a distinctive determinant of effective tumor suppression. Therefore, Rosa *et al.*¹⁹¹ respectively incorporated three different chemotherapeutic agents into PMMA and further co-cultured them with tumor cells to measure the viability of the tumor cells in each group by MTT assay. Although each group of drugs had a significant inhibitory impact on tumor cells within 24 h, the viability of the tumor cells was recovered to nearly 100% at 15 days as the drug concentration decreased.¹⁹¹ Accordingly, inferencing that the major drawback of drug-loaded PMMA cement involves the compact structure and extremely low porosity of PMMA cement, only a bit of initially burst drug was released, and over 80–90% of the drug was contained within the cement and was incapable of being released.¹⁶² Tumor cells with tenacious proliferative capacity are incapable of being effectively inhibited for a long time by the few drugs released rapidly.¹⁹¹

3.1.2 Porogens. To achieve an efficient rate of drug release, the intensive porosity of PMMA is critical. The connectivity of pores is constructed to provide pathways for drug release and even platforms for new bone growth by introducing porosity in PMMA cement.¹⁹² The anchoring effect of PMMA with bone will be enhanced if sufficient bone tissue is generated at the edge of PMMA and aseptic loosening will be prevented.¹⁹³ Achieving this effect is indispensable for porogens, which are mostly composed of volatile or soluble substances,¹⁹⁴ such as polyethylene glycol (PEG),¹⁶⁴ poly(lactic-co-glycolic acid) (PLGA),¹⁶⁵ carboxymethylcellulose (CMC),¹⁷⁰ carboxymethyl chitosan (CMCS),¹⁶⁶ and gelatin,¹⁶⁷ *etc.* However, porogens or large amounts of drugs could have deleterious effects on the mechanical properties of cement.¹⁹⁵ Therefore, the mechanical strength of PMMA ought to be emphasized in the process of providing a continuous release of drugs.

By incorporating PEG into PMMA, it is possible to increase the MTX-loaded elution to obtain even 60% of the total amount



of drugs. Although the changes in the mechanical properties of cement were not introduced in the article, they were presumably seriously weakened.¹⁶⁸ Improved mechanical properties could be presented by CMCS-modified PMMA; CMCS is a natural polysaccharide with water solubility and is associated with anti-tumor activity, according to research.^{196,197} Liu *et al.*¹⁹⁸ incorporated MTX and CMCS into PMMA-fabricated composite cement, providing a DDS with intensive drug release and more persistence than pure PMMA. Notably, the mechanical properties of the cement, as well as implant-bone integration were improved, and the possibility of secondary fracture was subsequently decreased. Moreover, a lower polymerization temperature and prolonged setting time of CMC-modified PMMA are well accepted for clinical application by surgeons.¹⁷⁰ During mixing, the hydrophilic CMC hydrogel was dispersed throughout the hydrophobic PMMA and left voids to form pores after aqueous CMC drying, creating 34–35% open porosity (Fig. 4). Nevertheless, 80% of the total loading drugs remained entrapped in cement, which was attributed to the hydrophobic nature of PMMA resulting in body fluid not penetrating PMMA to release the drugs. Therefore, some studies have indicated that PMMA particles modified with ovalbumin exhibited improved biocompatibility and hydrophilicity.¹⁸⁴ In addition, the refilling of chemotherapeutics can be achieved by a PMMA-based DDS modified with insoluble γ -cyclodextrin (γ -CD)

polymeric microparticles (a cyclic oligosaccharide), which can thermodynamically entrap and release DOX due to their binding strength and affinity.¹⁹⁹ PMMA/ γ -CD composite cement served as the first chemotherapeutic delivery system capable of refilling and consistently releasing DOX with sufficient mechanical properties, achieving the excellent effect of the inhibition of tumor cells. Therefore, a more pioneering opportunity for the modification of dense PMMA cement will be provided by continuous innovation and the development of porogens.

3.1.3 Radioisotopes. Radiotherapy is frequently applied for bone tumors,²⁰⁰ and greater efficacy will be achieved with the interstitial implantation of radioactive seeds.¹⁷¹ PVP combined with ¹²⁵Iodine seed implantation in the treatment of spinal metastases has manifested a considerable therapeutic effect,¹⁷² reducing its side effects and simultaneously enhancing its anti-tumor activity to target metastasis. In addition, discrepant effects will be presented by different radioisotopes due to their respective physical and biological properties.²⁰¹ Lu *et al.*¹⁷³ incorporated samarium-153-ethylenediamine tetramethylene phosphonate (¹⁵³Sm-EDTMP) into PMMA, injecting it into the vertebrae of dogs to investigate its safety and feasibility. The anti-tumor activity would be observably intensified without damaging adjacent tissues when the dose of ¹⁵³Sm-EDTMP is lower than 70 mCi.

3.2. Magnetic hyperthermia

Hyperthermia involves generating temperatures generally between 41–46 °C and eradicating tumor cells sensitive to temperature without adverse effects.²⁰² Magnetic hyperthermia, one of the types of hyperthermia, produces heat *via* magnetic nanoparticles (MNP) when exposed to the AMF.²⁰³ Based on this property, the incorporation of MNPs into PMMA has been investigated for the magnetic thermal therapy of bone tumors, providing reliable multifunctional therapeutic effects. The magnetic hyperthermia treatment has the following fundamental advantages when treating bone tumors locally: (1) the AMF penetrates deeper than any other activation mechanism (light or acoustic), allowing deeper tissue to be reached; (2) the nanoscale size drives the magnetic properties that determine the heating capacity.²⁰⁴ Notably, PMMA modified by different MNPs exhibits discrepancies, including oxides or alloys of magnetic elements such as iron, cobalt, and nickel.^{202,205} A composite PMMA cement incorporating magnetite-containing bioactive glass-ceramic exhibited thermal effects while still maintaining desirable mechanical properties without modulating the morphological, mechanical, and calorimetric characterization.²⁰⁶

Fe₃O₄ MNP is capable of generating effective magnetic thermal properties *via* the application of a controllable external AMF.^{207,208} However, the properties of Fe₃O₄-incorporated PMMA deserve to be further verified. Kawashita *et al.*¹⁷⁴ first comprehensively investigated the magnetic thermal ability, compressive property, setting time, and maximum temperature during the setting of Fe₃O₄-incorporated PMMA with different concentrations, showing the feasibility of Fe₃O₄-modified PMMA as a magnetic cement, but only *in vitro*. In subsequent



Fig. 4 Schematic representation of PMMA cement modified with porogens for the treatment of bone tumors. (A) Schematic illustration showing how dual-functional porous and cisplatin-loaded PMMA cement for the reconstruction of load-bearing bone defect kills bone tumor cells. (B) 2D micro-CT X-ray images of transversal cross-sections and 3D reconstructions of PMMA-based cement with different CMC content. The colorful shapes above indicate substantial porosity in the porous PMMA specimens. (C) Cytotoxic effects of 4% CMC-containing cisplatin-loaded PMMA cement release assessed by live/dead staining. Reproduced with permission.¹⁷⁰ Copyright 2022, Elsevier.



experiments by Ling *et al.*¹⁷⁵ Fe₃O₄-modified PMMA was applied to kill subcutaneous tumors *in vivo* through magnetic thermal treatment, showing a considerable anti-tumor effect. The temperature was mildly increased to simulate the clinical procedure in the spine.¹⁷⁶ In addition, a positive correlation between the coagulation necrosis area of tumor tissue and the concentrations of Fe₃O₄ was indicated¹⁷⁵ but the potential toxicity of Fe₃O₄ should not be ignored.²⁰⁹ Therefore, the quantity and dimensions of Fe₃O₄ MNP are crucial factors in the regulation of magnetic thermal capacity as well as possible cytotoxicity to tumor cells.^{210,211} The biosafety of PMMA-6% Fe₃O₄ presented no abnormal indicators regarding heart function, liver function, kidney function, and blood tests. In addition, excellent mechanical support was provided while simultaneously exhibiting the ideal magnetic thermal killing effect after minimally invasive injection into tibial tumor defects *in vivo* (Fig. 5).¹⁸⁰ Such magnetic thermal cement can also be applied as the DDS for synergistic magnetic thermal ablation and chemotherapy, which was achieved by a Fe₃O₄-modified PMMA mixed with DOX (DOX/Fe₃O₄@PMMA).⁴⁶ Excellent magnetic thermal properties and also the controllable release of DOX stimulated by AFM would be accomplished by DOX/Fe₃O₄@PMMA and without the presence of potential side effects. This novel cement is promising for clinical application in the efficient therapy of bone tumors.

In addition to Fe₃O₄, the reasonable addition of components will lead to cement with other aspects of improvement. Bone defects caused by bone tumors frequently pose intractable

problems for treatment and PMMA cement with TiO₂ can eliminate this problem.¹⁷⁹ PMMA cement containing 15% or more TiO₂ and 25% or more Fe₃O₄ has high bone affinity, forming apatite on their surfaces within 14 days in a simulated body fluid. This modified strategy provides a practical treatment option for patients with tumor-derived bone defects. Ren *et al.*¹⁷⁸ synthesized a novel composite PMMA consisting of Zn and Fe, which minimally affected the physicochemical properties of the cement, according to the requirements of clinical transformation. To further enhance the biological activity, silica-coated MNPs were fabricated for incorporation into PMMA.¹⁷⁷ The bioactive behavior was derived from the existence of Si-OH groups due to the silica shell, facilitating apatite nucleation.

In brief, enhancing the effectiveness of other treatments (radiotherapy, chemotherapy, immunotherapy, *etc.*) without increasing the toxicity is the most prominent contribution of thermotherapy, so the subsequent clinical application of magnetic thermal cement has a broader prospect. However, restricted by the magnetic field generator's fabrication technology and equipment requirements, the development of magnetic thermal cement remains to be explored and researched in a multidisciplinary manner.

4. Conclusion

The complex pathological mechanism of bone tumors not only presents severe challenges to patients but also perplexes surgeons. Patients are loath to tolerate persistent torment derived from bone tumors, including pain, neurological signs, bone instability, and tendencies to relapse. However, the current primary clinical treatment is insufficient, subjecting the patient to the restrictions of curettage, large bone defects, persistent pain, and high recurrence rates. Fortunately, as a commercial biomaterial, PMMA has the potential to address these issues based on the advantages of being plastic, injectable, and its prominent mechanical properties.

The margin of bone defects originating from osteolytic tumors or the curettage of tumors can be perfectly filled by PMMA cement with plasticity, providing stable mechanical support. Moreover, the residual tumor cells and eroded nociceptive nerve endings will be killed by the heat and chemically toxic substances generated from the exothermic polymerization reaction of PMMA. The pain felt by patients and the risk of recurrence will be reduced but there is no denying that the issue regarding whether PMMA can reduce the tumor recurrence rate is controversial, and additional complications will be certainly generated from the exothermic polymerization reaction of PMMA. Fortunately, researchers have gained extensive experience from previous failures due to medical negligence, and they avoid the occurrence of similar complications as much as possible to provide more dependable operational experience in the future. Notably, many projects for PMMA modification were also supposed to resolve the fundamental trouble caused by residual tumor cells. Whether PMMA is

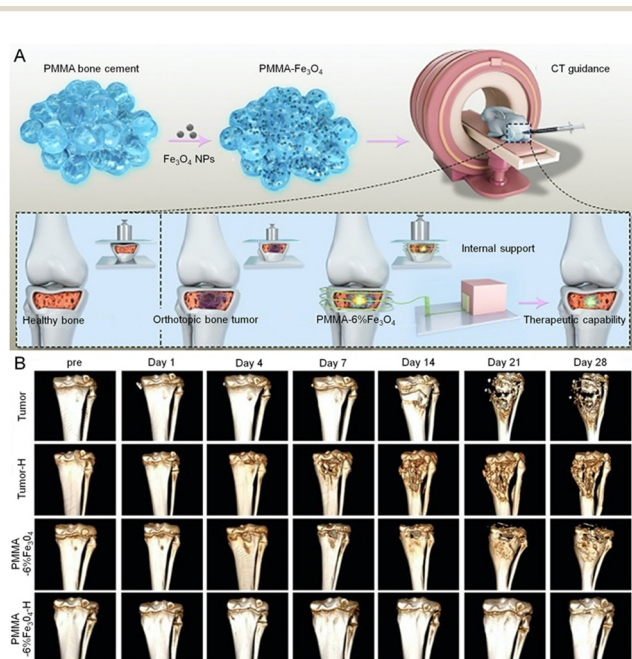


Fig. 5 Schematic representation of magnetothermal PMMA cement for the treatment of bone tumors. (A) Schematic illustration of PMMA-Fe₃O₄ cement for internal mechanical support and magnetic thermal ablation of bone tumors. (B) 3D-reconstructed CT images at each follow-up time point, the volume of bone defects in the PMMA-6%Fe₃O₄-H group increased slightly after the 28-day follow-up. Reproduced with permission.¹⁸⁰ Copyright 2019, Ivyspring International Publisher.



modified to DDS or magnetic thermal cement, residual tumor cells can be effectively eradicated on the premise of the invariable bottommost compressive properties and physicochemical properties of cement. Therefore, these projects offer progressive prospects for optimizing the treatment options and alleviating symptoms in patients in the future.

5. Prospects

The effectiveness of PMMA cement in the treatment of bone tumors deserves some appreciation and despite some complications, there are considerable prospects with the appropriate modifications. Although the stability of small bone defects can be reconstructed by PMMA cement, the ability is disputed when disposing of large defects.²¹² Implant loosening and failure are frequently attributed to the intrinsic cytotoxicity and bioinertness of PMMA.^{213,214} Inorganic bone cement is less toxic and more biocompatible but has not been extensively applied in bone tumor treatment.²¹⁵ Therefore, some researchers have incorporated inorganic cement or bioactive glasses into PMMA cement, accomplishing the improved modification of composite cement with excellent polymerization temperature, biocompatibility, and compressive properties.²¹⁶ Most significantly, the current work indicates that incorporating inorganic cement or bioactive glasses into PMMA cement facilitates pore construction, which is potentially adjunctive to the release of chemotherapeutic agents. The optimal mixing ratios are requisite for further research and continuous improvement and simultaneously, better biocompatibility will be demonstrated by mixing some additives in PMMA cement that are conducive to repairing tumor-derived bone defects.

PMMA cement loaded with drugs has considerable anti-tumor efficacy and conditions that damage healthy bone tissue are not unusual due to the rapid and massive release of drugs.¹⁸⁸ To construct a reasonable DDS based on PMMA cement, the particle size and concentration of diverse antineoplastic agents should be rigorously investigated. It is worth noting that alendronate, a prevalent anti-tumor drug incorporated into PMMA cement as a drug carrier can, in combination with the tumor microenvironmental response, block the exchange of substances between the tumor and the surrounding normal tissues.²¹⁷ This is a promising osmotic anti-tumor approach.²¹⁸ Immunotherapy is also included as it is involved in most physiological and pathological processes in the body.^{219,220} In addition, the sustained release effect of drugs can be achieved by porogen-modified PMMA cement, averting damage to healthy bone tissue and inhibiting residual tumor cells. However, current research on porogen-modified PMMA cement is inadequate for providing a reliable DDS for the clinical treatment of bone tumors. A type of PMMA cement modified by a specific porogen acts as a sustained drug release platform with the addition of replaceable drugs to achieve different therapeutic effects. In addition, because the most prominent contribution of hyperthermia is enhancing the effectiveness of other treatments (radiotherapy, chemotherapy,

immunotherapy, *etc.*) without increasing toxicity, a broad horizon for the efficient treatment of bone tumors is created by the development of magnetic thermal cement. At present, except for Fe₃O₄ MNP-modified PMMA cement, other types of MNP are few. The development of novel MNPs to modify PMMA cement could perhaps attain unexpected improvements. Nevertheless, the magnetic field generator's fabrication technology and equipment requirements consistently bewilder researchers. Photothermal therapy is also an optimal treatment for hyperthermia without requirements as stringent as magnetic thermal requirements, but the current research on photothermal PMMA cement applied to bone tumors is very sparse. In summary, PMMA cement plays an essential role in bone tumor treatment, with irreplaceable advantages and can be modified to achieve better therapeutic effects in the future.

Author contributions

Contributions: (I) conceptualization: Bo Chao, Zhonghan Wang, and Minfei Wu; (II) writing – original draft: Bo Chao; (III) funding acquisition: Jianhang Jiao, Zhonghan Wang, and Minfei Wu; (IV) writing – review & editing: Bo Chao, Jianhang Jiao, Lili Yang, Yang Wang, Tong Yu, He Liu, Han Zhang, Mufeng Li, Wenjie Wang, Xiangran Cui, Shangyu Du, Zhonghan Wang, and Minfei Wu.

Conflicts of interest

There is no conflict of interest to declare.

Acknowledgements

This work was supported by the Department of Science and Technology of Jilin Province (20210204104YY, YDZJ202201-ZYTS135, YDZJ202301ZYTS031, YDZJ202301ZYTS032), and Bethune Plan of Jilin University (Grant No. 2023B08, 2023B10).

References

- H. Sung, J. Ferlay, R. L. Siegel, M. Laversanne, I. Soerjomataram, A. Jemal and F. Bray, *Ca-Cancer J. Clin.*, 2021, **71**, 209–249.
- F. Verrecchia and F. Redini, *Front. Oncol.*, 2018, **8**, 133.
- S. De Salvo, V. Pavone, S. Coco, E. Dell'Agli, C. Blatti and G. Testa, *J. Clin. Med.*, 2022, **11**, 699.
- W. J. Anderson and L. A. Doyle, *Histopathology*, 2021, **78**, 644–657.
- P. S. Steeg, *Nat. Rev. Cancer*, 2016, **16**, 201–218.
- J. S. Whelan and L. E. Davis, *J. Clin. Oncol.*, 2018, **36**, 188–193, DOI: [10.1200/JCO.2017.75.1743](https://doi.org/10.1200/JCO.2017.75.1743).
- H. M. Zakaria, J. T. Llaniguez, E. Telemi, M. Chuang, M. Abouelleil, B. Wilkinson, A. Chandra, D. Boyce-Fappiano, E. Elibe, L. Schultz, F. Siddiqui, B. Griffith, S. N. Kalkanis, I. Y. Lee and V. Chang, *Neurosurgery*, 2020, **86**, 705–716.



- 8 L. van der Heijden, P. D. S. Dijkstra, J. Y. Blay and H. Gelderblom, *Eur. J. Cancer*, 2017, **77**, 75–83.
- 9 H. Li, J. Gao, Y. Gao, N. Lin, M. Zheng and Z. Ye, *Front. Oncol.*, 2020, **10**, 580–605.
- 10 J. M. Argiles, S. Busquets, B. Stemmler and F. J. Lopez-Soriano, *Nat. Rev. Cancer*, 2014, **14**, 754–762.
- 11 S. D'Oronzo, R. Coleman, J. Brown and F. Silvestris, *J. Bone Oncol.*, 2019, **15**, 100205.
- 12 D. M. Sciubba, R. J. Petteys, M. B. Dekutoski, C. G. Fisher, M. G. Fehlings, S. L. Ondra, L. D. Rhines and Z. L. Gokaslan, *J. Neurosurg. Spine*, 2010, **13**, 94–108.
- 13 J. Gill and R. Gorlick, *Nat. Rev. Clin. Oncol.*, 2021, **18**, 609–624.
- 14 M. U. Jawad, B. H. Pollock, E. Alvarez, J. R. Carr-Ascher, R. L. Randall and S. W. Thorpe, *Ann. Surg. Oncol.*, 2022, **29**, 4363–4372.
- 15 T. Winkler, F. A. Sass, G. N. Duda and K. Schmidt-Bleek, *Bone Joint Res.*, 2018, **7**, 232–243.
- 16 B. W. Tan, Q. Tang, Y. J. Zhong, Y. L. Wei, L. F. He, Y. T. Wu, J. B. Wu and J. F. Liao, *Int. J. Oral Sci.*, 2021, **13**, 9.
- 17 J. Liao, K. Shi, Y. Jia, Y. Wu and Z. Qian, *Bioact. Mater.*, 2021, **6**, 2221–2230.
- 18 F. Wu, J. Xu, M. Jin, X. Jiang, J. Li, X. Li, Z. Chen, J. Nie, Z. Meng and G. Wang, *Front. Mol. Biosci.*, 2022, **8**, 705148.
- 19 H. K. Brown, M. Tellez-Gabriel and D. Heymann, *Cancer Lett.*, 2017, **386**, 189–195.
- 20 X. Xue, H. Qu and Y. Li, *Exploration*, 2022, **2**, 20210134.
- 21 J. Garnon, L. Meylheuc, R. L. Cazzato, D. Dalili, G. Koch, P. Auloge, B. Bayle and A. Gangi, *Diagn. Interv. Imaging*, 2019, **100**, 743–752.
- 22 J. K. Liu, R. I. Apfelbaum, B. W. Chiles III and M. H. Schmidt, *Neurosurg. Focus*, 2003, **15**, E2–E2.
- 23 T. A. G. van Vugt, J. J. Arts and J. A. P. Geurts, *Front. Microbiol.*, 2019, **10**, 1626.
- 24 T. Jaeblo, *JAAOS – J. Am. Acad. Orthop. Surg.*, 2010, **18**, 297–305.
- 25 K. D. Kuehn, W. Ege and U. Gopp, *Orthop. Clin. North Am.*, 2005, **36**, 17–28.
- 26 E. C. Krishnan, C. Nelson and J. R. Neff, *Med. Phys.*, 1986, **13**, 233–239.
- 27 D. Gundapaneni and T. Goswami, *J. Appl. Biomater. Biomech.*, 2014, **12**, 193–202.
- 28 A. Gangi and X. Buy, *Semin. Interventional Radiol.*, 2010, **27**, 124–136.
- 29 E. B. Dolan, M. G. Haugh, D. Tallon, C. Casey and L. M. McNamara, *J. R. Soc., Interface*, 2012, **9**, 3503–3513.
- 30 G. W. Froschle, J. Mahlitz, H. U. Langendorff, E. Achilles, J. Pollock and K. H. Jungbluth, *Anticancer Res.*, 1997, **17**, 995–1002.
- 31 Y. i Kim, H. G. Kang, J. H. Kim, S. k Kim, P. P. Lin and H. S. Kim, *Bone Joint J. B*, 2016, **98**, 703–709.
- 32 A. Balestrino, S. Boriani, R. Cecchinato, A. Parafioriti, M. Gambarotti and A. Gasbarrini, *Eur. Spine J.*, 2020, **29**, 3157–3162.
- 33 R. P. Bhide, A. Barman, S. M. Varghese, A. Chatterjee, S. Mammen, J. George and R. Thomas, *Am. J. Phys. Med. Rehabil.*, 2014, **93**, 431–436.
- 34 S. Ramanathan, T. Vora, A. Gulia, A. Mahajan and S. Desai, *Skeletal Radiology*, 2017, **46**, 715–718.
- 35 I. Tran, U. Gerckens, J. Remig, G. Zintl and J. Textor, *Spine (Phila Pa 1976)*, 2013, **38**, E316–318.
- 36 M. Nagae, Y. Mikami, K. Mizuno, T. Harada, T. Ikeda, H. Tonomura, R. Takatori, H. Fujiwara and T. Kubo, *Medicine*, 2016, **95**, e5178.
- 37 P. C. Gerszten and E. A. Monaco III, *Neurosurg. Focus*, 2009, **27**, E9.
- 38 P. C. Gerszten and W. C. Welch, *J. Neurosurg. Spine*, 2007, **6**, 92–95.
- 39 L. van der Heijden, M. A. J. van de Sande, A. C. Heineken, M. Fiocco, R. G. H. H. Nelissen and P. D. S. Dijkstra, *J. Bone Jt. Surg., Am. Vol.*, 2013, **95**, e159.
- 40 Y. Araki, N. Yamamoto, K. Hayashi, A. Takeuchi, S. Miwa, K. Igarashi, Y. Taniguchi, H. Yonezawa, S. Morinaga and H. Tsuchiya, *JB JS open access*, 2020, **5**, e19.00068.
- 41 M.-P. Henrichs, J. Krebs, G. Gosheger, A. Streithueger, M. Nottrott, T. Sauer, S. Hoell, G. Singh and J. Harges, *World J. Surg. Oncol.*, 2014, **12**, 330.
- 42 H. M. Wang, C. S. Galasko, S. Crank, G. Oliver and C. A. Ward, *Clin. Orthop. Relat. Res.*, 1995, 173–186.
- 43 F. Greco, L. de Palma, N. Specchia, S. Jacobelli and C. Gaggini, *Orthopedics*, 1992, **15**, 189–194.
- 44 K. Koto, H. Murata, Y. Sawai, E. Ashihara, M. Horii and T. Kubo, *Oncol. Lett.*, 2017, **14**, 1648–1656.
- 45 H. Oezben, L. Eralp, G. Baysal, A. Cort, N. Sarkalkan and T. Ozben, *Acta Orthop. Et Traumatologica Turcica*, 2013, **47**, 184–192.
- 46 B. Liang, D. Zuo, K. Yu, X. Cai, B. Qiao, R. Deng, J. Yang, L. Chu, Z. Deng, Y. Zheng and G. Zuo, *Mater. Sci. Eng., C*, 2020, **108**, 110460.
- 47 F. De Tommasi, C. Massaroni, R. F. Grasso, M. Carassiti and E. Schena, *Sensors*, 2021, **21**, 5470.
- 48 Z. Huang, Z. Tian, M. Zhu, C. Wu and Y. Zhu, *Adv. Ther.*, 2021, **4**, 2000212.
- 49 M. Miola, A. Bellare, R. Gerbaldo, F. Laviano and E. Verne, *Ceram. Int.*, 2021, **47**, 17633–17643.
- 50 N. Alcorta-Sevillano, I. Macías, A. Infante and C. I. Rodríguez, *Cells*, 2020, **9**, 2630.
- 51 Y. L. Xia, H. Y. Wang, Y. H. Li and C. F. Fu, *Front. Mater.*, 2022, **9**, 929618.
- 52 F. Migliorini, G. La Padula, E. Torsiello, F. Spiezia, F. Oliva and N. Maffulli, *Eur. J. Med. Res.*, 2021, **26**, 118.
- 53 J. G. Seiler III and J. Johnson, *J. South. Orthop. Assoc.*, 2000, **9**, 91–97.
- 54 Y. Gong, B. Zhang and L. Yan, *Front. Mater.*, 2022, **9**, 912713.
- 55 G. Szczesny, M. Kopec, D. J. Politis, Z. L. Kowalewski, A. Lazarski and T. Szolc, *Materials*, 2022, **15**, 3622.
- 56 W. B. Jacobs and R. G. Perrin, *Neurosurg. Focus*, 2001, **11**, e10.
- 57 T. Mrozek, J. Spindel, L. Miszczczyk, B. Koczy, A. Chrobok, B. Pilecki, P. Tomasik and J. Matysiakiewicz, *Ortopedia, Traumatologia, Rehabilitacja*, 2005, **7**, 481–485.
- 58 W. B. Scoville, A. H. Palmer, K. Samra and G. Chong, *J. Neurosurg.*, 1967, **27**, 274–279.



- 59 K. M. I. Salem and C. G. Fisher, *Eur. Spine J.*, 2016, **25**, 3916–3922.
- 60 S. T. Sorensen, A. O. Kirkegaard, L. Carreon, R. Rousing and M. O. Andersen, *Spine J.*, 2019, **19**, 1067–1075.
- 61 M. Stangenberg, L. Viezens, S. O. Eicker, M. Mohme, K. C. Mende and M. Dreimann, *Neurosurg. Focus*, 2017, **43**, E3.
- 62 J. Wong, E. Chow, E. de Sa, C. Rowsell, L. Probyn, M. Christakis, E. Sinclair, C. Law and J. Finkelstein, *J. Palliative Med.*, 2009, **12**, 97–100.
- 63 G. Shi, F. Feng, C. Hao, J. Pu, B. Li and H. Tang, *J. Int. Med. Res.*, 2020, **48**, DOI: [10.1177/0300060519835084](https://doi.org/10.1177/0300060519835084).
- 64 J. S. Jang, S. H. Lee, C. H. Rhee and S. H. Lee, *J. Neurosurg.*, 2002, **96**, 131–134.
- 65 J.-w Tan, B.-h Shen, W. Du, J.-q Liu and S.-q Lu, *Chin. Med. J.*, 2013, **126**, 2495–2498.
- 66 F. Tao, Z. Shi, H. Tao, A. Wei, H. Tao, H. Cao, Y. Zhao, Y. Zhang and W. Xiang, *Br. J. Neurosurg.*, 2020, **34**, 308–312.
- 67 C. I. Cady-McCrea, J. C. Gilbert and M. A. Galgano, *World Neurosurg.*, 2021, **152**, 162–166.
- 68 R. L. Cazzato, J. Garnon, D. Dalili, P. A. Autrusseau, P. Auloge, P. De Marini, X. Buy, J. Palussiere and A. Gangi, *Tech. Vasc. Interventional Radiol.*, 2022, **25**, 00803.
- 69 M. T. Wallace and R. M. Henshaw, *J. Pediatr. Orthop.*, 2014, **34**, 92–100.
- 70 Y. Panchwagh, A. Puri, M. Agarwal, C. Anchan and M. Shah, *Indian J. Orthop.*, 2007, **41**, 139–145.
- 71 S. P. Gupta and G. Garg, *J. Orthop. Traumatol.*, 2016, **17**, 239–247.
- 72 A. F. Mavrogenis, V. G. Igoumenou, P. D. Megaloikononimos, G. N. Panagopoulos, P. J. Papagelopoulos and P. N. Soucacos, *Sicot-J*, 2017, **3**, 54.
- 73 J. Segura, J. Albareda, A. L. Bueno, A. Nuez, D. Palanca and F. Seral, *La Chirurgia degli organi di movimento*, 1997, **82**, 373–380.
- 74 Y. Song, C.-F. Li, X.-T. Shi, Y.-Q. Cheng, H.-Q. Suo and J.-G. Liu, *China J. Orthop. Traumatol.*, 2019, **32**, 372–376.
- 75 Q. Zhang, Y. Cai, X. Niu and L. Hao, *Chin. J. Surgery*, 1999, **37**, 730–732.
- 76 A. Zylberberg, G. Bayley, L. Gala and P. R. Kim, *Case Rep. Orthop.*, 2015, 283294.
- 77 S. Tsukamoto, A. F. Mavrogenis, M. Akahane, K. Honoki, A. Kido, Y. Tanaka, D. M. Donati and C. Errani, *BMC Musculoskeletal Disord.*, 2022, **23**, 477.
- 78 M. Wu, S. Yao, Y. Xie, F. Yan, Z. Deng, J. Lei and L. Cai, *Medicine*, 2018, **97**, e13154.
- 79 G. Guzik, *J. Orthop. Surg. Res.*, 2016, **11**, 54.
- 80 N. Sethakorn, E. Heninger, C. Sanchez-de-Diego, A. Ding, R. C. Yada, S. C. Kerr, D. Kosoff, D. J. Beebe and J. S. M. Lang, *Cancers*, 2022, **14**, 757.
- 81 R. E. Coleman, P. I. Croucher, A. R. Padhani, P. Clezardin, E. Chow, M. Fallon, T. Guise, S. Colangeli, R. Capanna and L. Costa, *Nat. Rev. Dis. Primers*, 2020, **6**, 83.
- 82 P. Romero-Morelos, E. Ruvalcaba-Paredes, D. Garciadiego-Cazares, M. PerezSantos, S. Reyes-Long, A. Alfaro-Rodriguez, M. Salcedo, J. Mancilla-Ramirez and C. Bandala, *Curr. Neuropharmacol.*, 2021, **19**, 308–319.
- 83 P. Mantyh, *Pain*, 2013, **154**, S54–S62.
- 84 N. Figura, J. Smith and H. H. M. Yu, *Hematol./Oncol. Clin. North Am.*, 2018, **32**, 447–458.
- 85 R. E. Coleman, *Cancer Treat. Rev.*, 2001, **27**, 165–176.
- 86 T. F. Jakobs, C. Trumm, M. Reiser and R. T. Hoffmann, *Eur. Radiol.*, 2007, **17**, 2166–2175.
- 87 B. Roedel, F. Clarencon, S. Touraine, E. Cormier, L. Molet-Benhamou, L. Le Jean, H. Brisse, S. Neuenschwander and J. Chiras, *J. Neuroradiol.*, 2015, **42**, 222–228.
- 88 L. Prié, P. Lagarde, J. Palussière, S. el Ayoubi, J. M. Dillhuydy, M. Durand, J. M. Vital and G. Kantor, *Cancer Radiother.*, 1997, **1**, 234–239.
- 89 H. A. Gilbert, A. R. Kagan, H. Nussbaum, A. R. Rao, J. Satzman, P. Chan, B. Allen and A. Forsythe, *AJR. Am. J. Roentgenol.*, 1977, **129**, 1095–1096.
- 90 O. Togao, F. Mihara, T. Yoshiura, T. Noguchi, Y. Kuwabara, K. Yoshimitsu and H. Honda, *Fukuoka igaku zasshi Hukuoka acta medica*, 2005, **96**, 93–99.
- 91 Y.-Y. Tseng, Y.-L. Lo, L.-H. Chen, P.-L. Lai and S.-T. Yang, *Surg. Neurol.*, 2008, **70**, 78–84.
- 92 P. Xie, Y. Zhao and G. Li, *Clin. Neurol. Neurosurg.*, 2015, **138**, 157–161.
- 93 L. Alvarez, A. Perez-Higueras, D. Quinones, E. Calvo and R. E. Rossi, *Eur. Spine J.*, 2003, **12**, 356–360.
- 94 Y. Y. Tseng, S. T. Yang, P. H. Tu, T. C. Yang and Y. L. Lo, *Chin. J. Minimally Invasive Neurosurg.*, 2008, **51**, 280–284.
- 95 J. S. Jang and S. H. Lee, *J. Neurosurg. Spine*, 2005, **2**, 243–248.
- 96 K. J. Murphy and H. Deramond, *Neuroimaging Clin. N. Am.*, 2000, **10**, 535–545.
- 97 A. Cotten, N. Boutry, B. Cortet, R. Assaker, X. Demondion, D. Leblond, P. Chastanet, B. Duquesnoy and H. Deramond, *Radiographics*, 1998, **18**, 311–320; discussion 320–313.
- 98 G. Saliou, E. M. Kocheida, P. Lehmann, C. Depriester, G. Paradot, D. Le Gars, A. Balut and H. Deramond, *Radiology*, 2010, **254**, 882–890.
- 99 G. Sun, L. Li, P. Jin, X. W. Liu and M. Li, *J. Surg. Oncol.*, 2014, **110**, 123–128.
- 100 G. Sun, P. Jin, M. Li, Y. Lu, X. Liu, F. Li, Z. Xie, J. Ding and Z. Peng, *Technol. Cancer Res. Treat.*, 2011, **10**, 267–274.
- 101 Y. Li, Y. F. Gu, Z. K. Sun, C. G. Wu, Y. D. Li, W. Wang, Y. C. Chen and J. Lu, *Eur. Radiol.*, 2013, **23**, 2754–2763.
- 102 J. H. Woo, H. S. Park, J. I. Han and D. Y. Kim, *Pain Physician*, 2013, **16**, E405–E410.
- 103 J. W. Park, H.-j Lim, H. G. Kang, J. H. Kim and H.-S. Kim, *Ann. Surg. Oncol.*, 2022, **29**, 1413–1422.
- 104 I. Laufer, A. Hanover, E. Lis, Y. Yamada and M. Bilsky, *J. Neurosurg. Spine*, 2010, **13**, 109–115.
- 105 D. Lau, M. R. Leach, F. La Marca and P. Park, *J. Neurosurg. Spine*, 2012, **17**, 565–576.
- 106 M. Campanacci, N. Baldini, S. Boriani and A. Sudanese, *J. Bone Jt. Surg. Am.*, 1987, **69**, 106–114.
- 107 A. H. Kivioja, C. Blomqvist, K. Hietaniemi, C. Trovik, A. Walloe, H. C. Bauer, P. H. Jorgensen, P. Bergh and G. Follerås, *Acta Orthop.*, 2008, **79**, 86–93.



- 108 W. T. Becker, J. Dohle, L. Bernd, A. Braun, M. Cserhati, A. Enderle, L. Hovy, Z. Matejovsky, M. Szendroi, K. Trieb and P. U. Tunn, *J. Bone Jt. Surg Am.*, 2008, **90**, 1060–1067.
- 109 D. Zuo, L. Zheng, W. Sun, D. Fu, Y. Hua and Z. Cai, *World J. Surg. Oncol.*, 2013, **11**, 148.
- 110 M. Balke, H. Ahrens, A. Streitbuerger, G. Koehler, W. Winkelmann, G. Gosheger and J. Hardes, *J. Cancer Res. Clin. Oncol.*, 2009, **135**, 149–158.
- 111 M. Balke, L. Schremper, C. Gebert, H. Ahrens, A. Streitbuerger, G. Koehler, J. Hardes and G. Gosheger, *J. Cancer Res. Clin. Oncol.*, 2008, **134**, 969–978.
- 112 P. H. Vora, R. Musa, N. M. Bhavsar and D. Shah, *J. Orthop. Case Rep.*, 2017, **7**, 68–71.
- 113 O. Ofluoglu, *Acta Orthop. Belg.*, 2008, **74**, 831–836.
- 114 E. Sirin, A. H. Akgulle, O. M. Topkar, O. Sofulu, S. E. Baykan and B. Erol, *Acta Orthop. Et Traumatol. Turcica*, 2020, **54**, 524–529.
- 115 N. G. Harness and H. J. Mankin, *J. Hand Surg. Am.*, 2004, **29**, 188–193.
- 116 Y.-p Liu, K.-h Li and B.-h Sun, *Clin. Orthop. Related Res.*[®], 2012, **470**, 2886–2894.
- 117 J. Bickels and D. A. Campanacci, *J. Bone Jt. Surg. Am. Vol.*, 2020, **102**, 164–174.
- 118 C. Errani, P. Ruggieri, M. A. N. Asenzio, A. Toscano, S. Colangeli, E. Rimondi, G. Rossi, A. Longhi and M. Mercuri, *Cancer Treat. Rev.*, 2010, **36**, 1–7.
- 119 T. Ozalp, H. Yercan, G. Okçu, O. Ozdemir and E. Coşkunol, *Acta Orthop. Traumatol. Turc*, 2006, **40**, 144–150.
- 120 W. Becker, *Z. Orthop. Ihre Grenzgeb.*, 1989, **127**, 379–381.
- 121 T. Wada, M. Kaya, S. Nagoya, S. Kawaguchi, K. Isu, T. Yamashita, S. Yamawaki and S. Ishii, *J. Orthop. Sci.*, 2002, **7**, 194–198.
- 122 S. Yevich, L. Tselikas, G. Gravel, T. de Baere and F. Deschamps, *Semin. Interventional Radiol.*, 2018, **35**, 268–280.
- 123 D. A. Nelson, M. E. Barker and B. H. Hamlin, *Int. J. Hyperthermia*, 1997, **13**, 287–306.
- 124 S. Aydin, E. Bozdog, E. Sunbuloglu, H. Unalan, M. Hanci, O. Aydingoz and C. Kaday, *Eur. Spine J.*, 2006, **15**, 341–346.
- 125 B. R. Radev, J. A. Kase, M. J. Askew and S. D. Weiner, *J. Biomech.*, 2009, **42**, 1120–1126.
- 126 B. Bombardier, D. Haase, K. Sweeney, E. Friedman, T. Poppe and N. Hughes, *J. Surg. Oncology*, 2021, **123**, 1299–1303.
- 127 D. Clarke, D. Nepaul, H. Chindapalli and K. Lawson, *West Indian Med. J.*, 2018, **67**, 148–152.
- 128 J. Benevenia, S. M. Rivero, J. Moore, J. A. Ippolito, D. A. Siegeman, K. S. Beebe and F. R. Patterson, *Clin. Orthop. Relat. Res.*, 2017, **475**, 776–783.
- 129 K. Y. Huang, J. J. Yan and R. M. Lin, *Spine*, 2005, **30**, E585–E588.
- 130 L. A. Thomson, F. C. Law, K. H. James, C. A. Matthew and N. Rushton, *Biomaterials*, 1992, **13**, 811–818.
- 131 X. Shi, Y. Cui, Y. Pan, B. Wang and M. Lei, *BMC Cancer*, 2021, **21**, 764.
- 132 K. Kita, Y. Takata, K. Higashino, K. Yamashita, F. Tezuka, T. Sakai, A. Nagamachi and K. Saiyo, *Surg. J.*, 2017, **3**, e1–e5.
- 133 S.-L. Zhang, B. Xu, Y.-J. Lao and H.-F. Sheng, *China J. Orthop. Traumatol.*, 2021, **34**, 738–742.
- 134 Y. Cui, Y. Pan, Y. Lin, C. Mi, B. Wang and X. Shi, *J. Orthop. Sci.*, 2022, **27**, 79–83.
- 135 L. Wang, C. Zhang, H. Liang, T. Huang, W. Zhong, Z. Zhao and X. Luo, *World J. Surg. Oncol.*, 2022, **20**, 112.
- 136 H. Sun, Z. Yang, Y. Xu, X. Liu, Y. Zhang, Y. Chen, D. Xu, Y. Yang, D. Li and J. Xia, *Eur. Spine J.*, 2015, **24**, 1768–1777.
- 137 A. O. Kirkegaard, S. T. Sorensen, D. S. Ziegler, L. Carreon, M. O. Andersen and R. Rousing, *Danish Med. J.*, 2018, **65**, A5509.
- 138 Q.-H. Tian, X.-Q. Sun, Y.-Y. Lu, T. Wang, C.-G. Wu, M.-H. Li and Y.-S. Cheng, *J. Vasc. Int. Radiol.*, 2016, **27**, 1420–1424.
- 139 F.-A. Wang, S.-C. He, E.-H. Xiao, S.-X. Wang, L. Sun, P.-H. Lv and W.-N. Huang, *Pain Physician*, 2016, **19**, E559–E567.
- 140 L. Wu, J. Fan, Q. Yuan, X. Zhang, M. Hu and K. Zhang, *Int. J. Hyperthermia*, 2021, **38**, 1069–1076.
- 141 A. Baumann, J. Tauss, G. Baumann, M. Tomka, M. Hessinger and K. Tiesenhausen, *Eur. J. Vasc. Endovasc. Surg.*, 2006, **31**, 558–561.
- 142 S. Telera, N. Gorgoglione, L. Raus, A. Vidiri, V. Villani, A. Pace, A. Fabi, F. Crispo, M. Castiglione, I. Sperduti and R. Boccaletti, *World Neurosurg.*, 2019, **127**, E751–E760.
- 143 I. Panagiotis, K. Panagiotis and V. Vasilios, *Eur. Spine J.*, 2014, **23**, S187–S191.
- 144 S. F. Hassani, E. Cormier, E. Shotar, M. Drir, J. P. Spano, L. Morardet, J. P. Collet, J. Chiras and F. Clarencon, *Eur. Radiol.*, 2019, **29**, 663–673.
- 145 F. Monticelli, H. J. Meyer and E. Tutsch-Bauer, *Forensic Sci. Int.*, 2005, **149**, 35–38.
- 146 Y. Zhang, X. Liu and H. Liu, *Orthop. Surg.*, 2022, **14**, 456–460.
- 147 N. Aebli, J. Krebs, G. Davis, M. Walton, M. J. A. Williams and J. C. Theis, *Spine*, 2002, **27**, 460–466.
- 148 H. Ahmadzai, S. Campbell, C. Archis and W. A. Clark, *Spine J.*, 2014, **14**, E1–E5.
- 149 H. Feng, J. Wang, P. Guo, J. Xu, W. Chen and Y. Zhang, *Pain Physician*, 2016, **19**, E767–E773.
- 150 K. Li, J. Yan, Q. Yang, Z. Li and J. Li, *J. Orthop. Surg. Res.*, 2015, **10**, 20.
- 151 S. Hoppe, T. Elfiky, M. J. B. Keel, E. Aghayev, T. M. Ecker and L. M. Benneker, *Eur. Spine J.*, 2016, **25**, 3463–3469.
- 152 P. F. Heini and R. Orler, *Orthopade*, 2004, **33**, 22–30, DOI: [10.1007/s00132-003-0574-3](https://doi.org/10.1007/s00132-003-0574-3).
- 153 J. M. Mathis, *Am. J. Neuroradiol.*, 2003, **24**, 1697–1706.
- 154 F. H. Cornelis, F. Petitpierre, T. Fabre, O. Gille, N. Amoretti and O. Hauger, *Eur. Radiol.*, 2017, **27**, 3942–3946.
- 155 G. C. Anselmetti, A. Manca, S. Tutton, G. Chiara, A. Kelekis, F. R. Facchini, F. Russo, D. Regge and F. Montemurro, *Pain Physician*, 2013, **16**, E397–E404.
- 156 S. Tang, W. Fu, H. Zhang, H. Zhang and B. Liang, *World Neurosurg.*, 2019, **132**, E739–E745.
- 157 W. Wang, H. Liu, Z. Wu, Y. Teng, Y. Huang, T. Liu and H. Yang, *Geriatric Orthop. Surg. Rehabil.*, 2022, **13**, DOI: [10.1177/21514593221119625](https://doi.org/10.1177/21514593221119625).



- 158 R. Mohamed, C. Silbermann, A. Ahmari, M. Bohner, S. Becker and G. Baroud, *Spine*, 2010, **35**, 353–360.
- 159 M. Inoue, M. Sakane and T. Taguchi, *J. Biomed. Mater. Res. Part B Appl. Biomater.*, 2014, **102**, 1786–1791.
- 160 T.-H. Leu, Y. Wei, Y.-S. Hwua, X.-J. Huang, J.-T. Huang and R.-J. Chung, *Polymers*, 2019, **11**, 1971.
- 161 J. H. Healey, F. Shannon, P. Boland and G. R. DiResta, *Clin. Orthop. Relat. Res.*, 2003, S263–S275, DOI: [10.1097/01.blo.0000093053.96273.ee](https://doi.org/10.1097/01.blo.0000093053.96273.ee).
- 162 G. Maccauro, A. Cittadini, M. Casarci, F. Muratori, D. De Angelis, C. Piconi, M. A. Rosa, A. Spadoni, M. Braden and A. Sgambato, *J. Mater. Sci. Mater. Med.*, 2007, **18**, 839–844.
- 163 R. Llombart-Blanco, C. Villas, A. Silva, A. Aldaz, I. Navarro, J. Forteza, S. Martin Algarra and M. Alfonso, *Eur. Spine J.*, 2017, **26**, 3216–3224.
- 164 L. Bao, X. Li, Y. Qi, Z. Wang and J. Li, *Chem. Eng. Sci.*, 2020, **215**, 115379.
- 165 M. Shi, J. D. Kretlow, A. Nguyen, S. Young, L. S. Baggett, M. E. Wong, F. K. Kasper and A. G. Mikos, *Biomaterials*, 2010, **31**, 4146–4156.
- 166 B. M. Liu, M. Li, B. S. Yin, J. Y. Zou, W. G. Zhang and S. Y. Wang, *PLoS One*, 2015, **10**, e0144407.
- 167 X. Zheng, Y. Wang, J. Liu, J. Han, Z. Cui, S. Wu, Y. Liang, S. Zhu, X. Ge and Z. Li, *Mater. Res. Express*, 2022, **9**, 035405.
- 168 J. A. Handal, N. C. Tiedeken, G. E. Gershkovich, J. A. Kushner, B. Dratch and S. P. Samuel, *J. Surg. Res.*, 2015, **194**, 161–166.
- 169 E. L. Cyphert, N. Kanagasegar, N. Zhang, G. D. Learn and H. A. von Recum, *Macromol. Biosci.*, 2022, **22**, e2100415.
- 170 Z. Wang, L. P. Nogueira, H. J. Haugen, I. C. M. Van der Geest, P. C. D. A. Rodrigues, D. Janssen, T. Bitter, J. J. J. P. van den Beucken and S. C. G. Leeuwenburgh, *Bioact. Mater.*, 2022, **15**, 120–130.
- 171 Z. Yang, D. Yang, L. Xie, Y. Sun, Y. Huang, H. Sun, P. Liu and Z. Wu, *Acta Radiol.*, 2009, **50**, 1142–1148.
- 172 S. Wang, G. Shi and X. Meng, *Pak. J. Pharm. Sci.*, 2015, **28**, 1039–1042.
- 173 J. Lu, J. Deng, H. Zhao, M. Shi, J. Wang and L. Zhao, *Eur. J. Radiol.*, 2011, **78**, 296–301.
- 174 M. Kawashita, K. Kawamura and Z. Li, *Acta Biomater.*, 2010, **6**, 3187–3192.
- 175 Y. Ling, X. Tang, F. Wang, X. Zhou, R. Wang, L. Deng, T. Shang, B. Liang, P. Li, H. Ran, Z. Wang, B. Hu, C. Li, G. Zuo and Y. Zheng, *RSC Adv.*, 2017, **7**, 2913–2918.
- 176 M. Harabech, N. R. Kiselovs, W. Maenhoudt, G. Crevecoeur, D. Van Roost and L. Dupre, *AIP Adv.*, 2017, **7**, 056704.
- 177 M. Miola, A. Bellare, F. Laviano, R. Gerbaldo and E. Verne, *Ceram. Int.*, 2019, **45**, 14533–14545.
- 178 B. Ren, Z. Han, W. Li and J. Liu, *Life-Basel*, 2022, **12**, 1342.
- 179 M. Kubota, T. Yokoi, T. Ogawa, S. Saito, M. Furuya, K. Yokota, H. Kanetaka, B. Jeyadevan and M. Kawashita, *Ceram. Int.*, 2021, **47**, 12292–12299.
- 180 K. Yu, B. Liang, Y. Zheng, A. Exner, M. Kolios, T. Xu, D. Guo, X. Cai, Z. Wang, H. Ran, L. Chu and Z. Deng, *Theranostics*, 2019, **9**, 4192–4207.
- 181 K. M. Zekry, N. Yamamoto, K. Hayashi, A. Takeuchi, A. Z. A. A. Alkhoodly, A. S. Abd-Elfattah, A. N. S. Elsaid, A. R. Ahmed and H. Tsuchiya, *J. Orthop. Surg.*, 2019, **27**, DOI: [10.1177/2309499019832970](https://doi.org/10.1177/2309499019832970).
- 182 B. A. Hain and D. L. Waning, *Curr. Osteoporosis Rep.*, 2022, **20**, 433–441.
- 183 V. Schirrmacher, *Int. J. Oncol.*, 2019, **54**, 407–419.
- 184 S. Prabakaran, M. Jeyaraj, A. Nagaraj, K. K. Sadasivuni and M. Rajan, *Appl. Nanosci.*, 2019, **9**, 1487–1500.
- 185 K. E. Marks, C. L. Nelson and E. P. Lautenschlager, *J. Bone Joint Surgery. Am. Vol.*, 1976, **58**, 358–364.
- 186 C. D. Pargas, A. H. Elhessy, M. Abouei, M. G. Gesheff and J. D. Conway, *Antibiotics*, 2022, **11**, 336.
- 187 V. Wall, T.-H. Nguyen, N. Nguyen and P. A. Tran, *Biomedicines*, 2021, **9**, 26.
- 188 F. G. Draenert and K. Draenert, *Chemotherapy*, 2008, **54**, 412–416.
- 189 S. Decker, W. Winkelmann, B. Nies and F. van Valen, *J. Bone Jt. Surg. Br. Vol.*, 1999, **81**, 545–551.
- 190 E. Prochazka, T. Soukup, M. Hroch, L. Fuksa, E. Brcakova, J. Cermanova, G. Kolouchova, K. Urban, J. Mokry and S. Micuda, *Int. Orthop.*, 2010, **34**, 137–142.
- 191 M. A. Rosa, G. Maccauro, A. Sgambato, R. Ardito, G. Falcone, V. De Santis and F. Muratori, *J. Bone Jt. Surg. Br. B Vol.*, 2003, **85**, 712–716.
- 192 Y. Sa, F. Yang, Y. N. Wang, J. G. C. Wolke and J. A. Jansen, in *Cutting-Edge Enabling Technologies for Regenerative Medicine*, ed. H. J. Chun, C. H. Park, I. K. Kwon and G. Khang, 2018, vol. 1078, pp. 119–134.
- 193 H. Wang, W. Zhi, X. Lu, X. Li, K. Duan, R. Duan, Y. Mu and J. Weng, *Acta Biomater.*, 2013, **9**, 8413–8421.
- 194 S. V. Dorozhkin, *Biomaterials*, 2010, **31**, 1465–1485.
- 195 M. Shi, J. D. Kretlow, P. P. Spicer, Y. Tabata, N. Demian, M. E. Wong, F. K. Kasper and A. G. Mikos, *J. Controlled Release*, 2011, **152**, 196–205.
- 196 C. Chen, Z. Gao, X. Qiu and S. Hu, *Molecules*, 2013, **18**, 7239–7252.
- 197 M. Gumińska, J. Ignacak and E. Wójcik, *Pol. J. Pharmacol.*, 1996, **48**, 495–501.
- 198 B.-M. Liu, M. Li, B.-S. Yin, J.-Y. Zou, W.-G. Zhang and S.-Y. Wang, *PLoS One*, 2015, **10**, e0144407.
- 199 E. L. Cyphert, N. Kanagasegar, N. Zhang, G. D. Learn and H. A. von Recum, *Macromol. Biosci.*, 2022, **22**, e2100415.
- 200 S. Faruqi, C.-L. Tseng, C. Whyne, M. Alghamdi, J. Wilson, S. Myrehaug, H. Soliman, Y. Lee, P. Maralani, V. Yang, C. Fisher and A. Sahgal, *Neurosurgery*, 2018, **83**, 314–322.
- 201 A. E. Hirsch, B. S. Rosenstein, D. C. Medich, C. B. Martel and J. A. Hirsch, *Pain Physician*, 2009, **12**, 887–891.
- 202 S. S. Danewalia and K. Singh, *Mater. Today Bio*, 2021, **10**, 100100.
- 203 A. M. Derfus, G. von Maltzahn, T. J. Harris, T. Duza, K. S. Vecchio, E. Ruoslahti and S. N. Bhatia, *Adv. Mater.*, 2007, **19**, 3932–3936.
- 204 E. A. Perigo, G. Hemery, O. Sandre, D. Ortega, E. Garaio, F. Plazaola and F. J. Teran, *Appl. Phys. Rev*, 2015, **2**, 041302.



- 205 P. B. Santhosh and N. P. Ulrich, *Cancer Lett.*, 2013, **336**, 8–17.
- 206 M. Bruno, M. Miola, O. Bretcanu, C. Vitale-Brovarone, R. Gerbaldo, F. Laviano and E. Verne, *J. Biomater. Appl.*, 2014, **29**, 254–267.
- 207 H. Huang, S. Delikanli, H. Zeng, D. M. Ferkey and A. Pralle, *Nat. Nanotechnol.*, 2010, **5**, 602–606.
- 208 B. Thiesen and A. Jordan, *Int. J. Hyperthermia*, 2008, **24**, 467–474.
- 209 T. J. Gutiérrez and V. A. Alvarez, in *Handbook of Nanomaterials for Industrial Applications*, ed. C. Mustansar Hussain, Elsevier, 2018, pp. 563–576, DOI: [10.1016/B978-0-12-813351-4.00032-8](https://doi.org/10.1016/B978-0-12-813351-4.00032-8).
- 210 Z. Li, M. Kawashita, N. Araki, M. Mitsumori, M. Hiraoka and M. Doi, *Mater. Sci. Eng., C*, 2010, **30**, 990–996.
- 211 M. Ma, Y. Wu, J. Zhou, Y. Sun, Y. Zhang and N. Gu, *J. Magn. Mater.*, 2004, **268**, 33–39.
- 212 Y. Xia, H. Wang, Y. Li and C. Fu, *Front. Mater.*, 2022, **9**, 929618.
- 213 C. Wang, X. Wang, X.-L. Xu, X.-L. Yuan, W.-L. Gou, A.-Y. Wang, Q.-Y. Guo, J. Peng and S.-B. Lu, *PLoS One*, 2014, **9**, 0096361.
- 214 Y. Tamaki, K. Sasaki, A. Sasaki, Y. Takakubo, H. Hasegawa, T. Ogino, Y. T. Konttinen, J. Salo and M. Takagi, *J. Biomed. Mater. Res. Part B Appl. Biomater.*, 2008, **84**, 191–204.
- 215 O. Demir-Oguz, A. R. Boccaccini and D. Loca, *Bioact. Mater.*, 2023, **19**, 217–236.
- 216 W. Liu, Z. Huan, C. Wu, Z. Zhou and J. Chang, *Composites, Part B*, 2022, **247**, 110324.
- 217 Y. Liu, Z. Y. Jiang, S. Z. Tong, Y. F. Sun, Y. Zhang, J. Y. Zhang, D. Y. Zhao, Y. Z. Su, J. X. Ding and X. S. Chen, *Adv. Mater.*, 2023, **35**, 2203291.
- 218 Z. Y. Jiang, Y. Liu, R. Shi, X. R. Feng, W. G. Xu, X. L. Zhuang, J. X. Ding and X. S. Chen, *Adv. Mater.*, 2022, **34**, 2110094.
- 219 D. Li, S. Liu, Y. Ma, S. Liu, Y. Liu and J. Ding, *Small Methods*, 2023, **7**, e2300204.
- 220 J. Zhang, D. Tong, H. Song, R. Ruan, Y. Sun, Y. Lin, J. Wang, L. Hou, J. Dai, J. Ding and H. Yang, *Adv. Mater.*, 2022, **34**, e2202044.

